



Published in final edited form as:

ASAIO J. 2014 ; 60(6): 742–743. doi:10.1097/MAT.000000000000124.

## Robotic Assisted Implantation of Ventricular Assist Device after Sternectomy & Pectoralis Muscle Flap

Zain Khalpey, MD, PhD, MRCS(Eng)<sup>a,d,f</sup>, Nicole Sydow, MD<sup>a</sup>, Samata Paidy, MD<sup>b</sup>, Marvin J. Slepian, MD<sup>c,d</sup>, Mark Friedman, MD<sup>c</sup>, Anthony Cooper, CSFA<sup>a</sup>, Katherine M. Marsh, BS<sup>a</sup>, Jan D Schmitto, MD<sup>e</sup>, and Robert Poston, MD<sup>a</sup>

<sup>a</sup>Department of Cardiothoracic Surgery, University of Arizona, Tucson, AZ

<sup>b</sup>Department of Anesthesia, University of Arizona, Tucson, AZ

<sup>c</sup>Division of Cardiology, Sarver Heart Center, University of Arizona, Tucson, AZ

<sup>d</sup>Department of BioMedical Engineering, University of Arizona, Tucson, AZ

<sup>e</sup>Department of Physiological Sciences, University of Arizona, Tucson, AZ

<sup>f</sup>Department of Cardiothoracic, Transplant and Vascular Surgery, Hannover Medical School, Hannover, Germany

### Abstract

Left ventricular assist devices are increasingly important in the management of advanced heart failure. Most patients who benefit from these devices have had some prior cardiac surgery, making implantation of higher risk. This is especially true in patients who have had prior pectoralis flap reconstruction after sternectomy for mediastinitis. We outline the course of such a patient, in whom the use of robotic assistance allowed for a less invasive device implantation approach with preservation of the flap for transplantation.

### Keywords

Robotics; Heart Failure; Device; Minimally Invasive Surgery

### Introduction

Left ventricular assist devices (LVAD) significantly improve the quality of life and reduce mortality of patients with advanced heart failure.[1] LVAD outcomes continue to improve, yet there remain unavoidable consequences of implantation. Because many LVAD candidates have had prior cardiac surgery, an important dilemma is the need for re-do sternotomy during implant and again during heart transplant when the device is used as a

---

Copyright © 2014 by the American Society for Artificial Internal Organs

Corresponding Author: Dr. Zain Khalpey, 1501 N Campbell Ave., Tucson, AZ 85724, Office: (520) 626-6339, Fax: (520) 626-4042, zkhalpey@surgery.arizona.edu.

**Publisher's Disclaimer:** Disclaimers: Authors have nothing to disclose with regard to commercial support and have no conflicts of interest.

bridge to transplant. Re-do sternotomy places patients at greater risk for mortality, major morbidity, and increased resource utilization (e.g. blood transfusions, length of stay).[2] These patients often have dilated right ventricles (RV) that are adherent to the sternum and therefore prone to injury associated with an increased mortality rate.[3] Direct cardiac dissection of adhesions can be poorly tolerated, prolong cardiopulmonary bypass (CPB) times and lead to bleeding, excessive transfusions and inflammation, well known triggers for postoperative RV failure. As the majority of our referrals for LVAD have had prior sternotomies, we sought to determine the utility of robotics as a way to reduce the morbidity of this procedure.

## Patient and Methods

A 66 year old man with ischemic cardiomyopathy was evaluated for LVAD implantation after admission for decompensated heart failure. The patient had previously undergone CABG and developed mediastinitis requiring sternectomy with pectoralis flap reconstruction. A traditional sternotomy approach to LVAD implantation was undesirable due to the risks of mediastinal bleeding, flap necrosis and wound complications. This patient was also considered a transplant candidate and a second incision through the flap at time of transplant would be extremely high risk for wound complications.

In order to preserve the pectoralis flap, a HeartWare left ventricular assist device (hVAD, HeartWare International Inc., Framingham, MA) was implanted via a left mini-thoracotomy incision with the assistance of the da Vinci robot (Intuitive Surgical, Sunnyvale, CA).

With the patient in supine position, the right femoral vessels were cannulated for CPB. A 4cm left anterior thoracotomy was made over the cardiac apex as defined by intra-operative transthoracic echocardiography. Limited dissection was used to expose the apex of the heart and the inflow sewing ring was sutured into place. The pump was positioned within the left thorax, and the drive line was tunneled subcutaneously over the lower ribs.

Three robotic ports were placed in the right chest via the 2<sup>nd</sup>, 4<sup>th</sup> and 6<sup>th</sup> intercostal spaces in the anterior axillary line (Figure 1). Robotic instruments were employed to separate the right ventricle from the overlying pectoralis flap to create a tunnel across the chest to the thoracotomy wound (Figure 2). The outflow graft was then passed through the mediastinal tunnel into the right chest for anastomosis with the aorta. This was done under direct visualization to prevent kinking.

A side-biting clamp was placed onto the ascending aorta via a small incision in the upper midline through the proximal 2 cm of the flap. CPB was initiated and the left ventricle was cored and the hVAD attached. The outflow cannula was then anastomosed to the aorta. Once in place, flow through the device was initiated, and an angiocath was placed into the outflow graft for de-airing. The device was covered with a Gore-Tex Soft Tissue Patch (W. L. Gore and Associates, Inc., Newark, DE) to minimize adhesions to the lung.

## Results

The CPB time was 68 minutes, and 2 units of packed red blood cells were given intra-operatively. Of note, the patient had pre-operative RV dysfunction determined by nuclear imaging and echocardiography. Despite this, the patient did not developed post-operative RV failure.

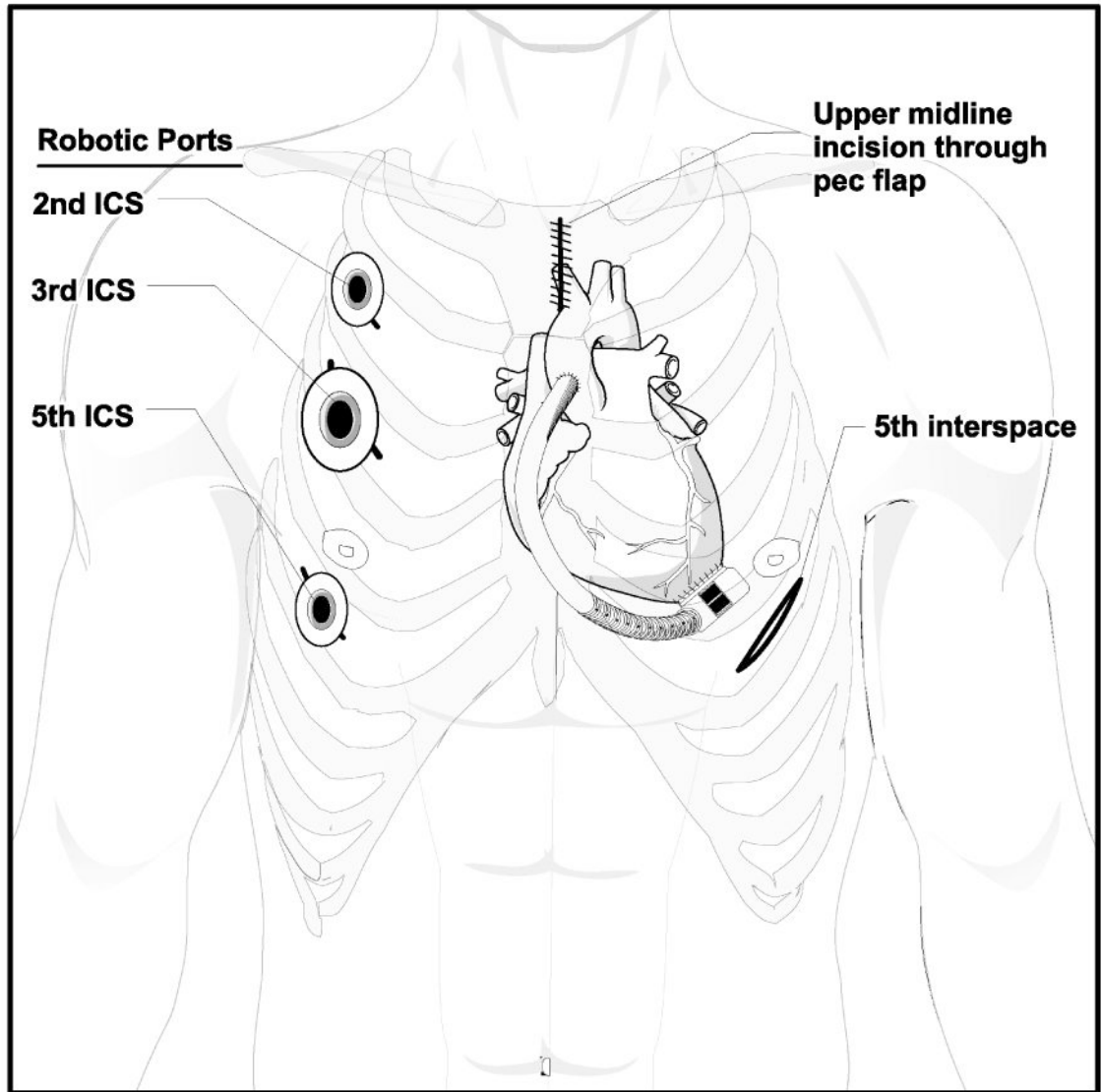
## Conclusion

As confidence grows in LVAD support for severe heart failure, it is likely that re-do sternotomy will become increasingly common.[4] This presents a dilemma as re-operative sternotomy at time of transplantation has been associated with decreased short and long-term survival. In order to avoid re-do sternotomy, new methods of LVAD implantation must be explored, particularly as new generation devices become smaller and more conducive to less invasive implantation. The existing minimally invasive approaches which involve anastomosis to the aorta include either implantation via a J ministernotomy with extension into the right third intercostal space and minithoracotomy through the left fifth intercostal space or via the Viennese method, which includes minithoracotomies through the left fourth or fifth intercostal space and right second intercostal space.[5,6] Anastomosis of the outflow graft to peripheral sources such as the left subclavian artery was not desirable due to the non-physiologic blood pressure and bidirectional flow which occurs in the subclavian as a result. [7] Our approach improves on previously described non-robotic thoracotomy approaches as it provides optimal visualization for RV dissection with reduced risk of kinking of the outflow graft while still allowing anastomosis to the aorta. Robotics could also facilitate the aortic anastomosis through the right chest ports, further decreasing mediastinal dissection and improving outcomes in these patients at the time of transplantation.

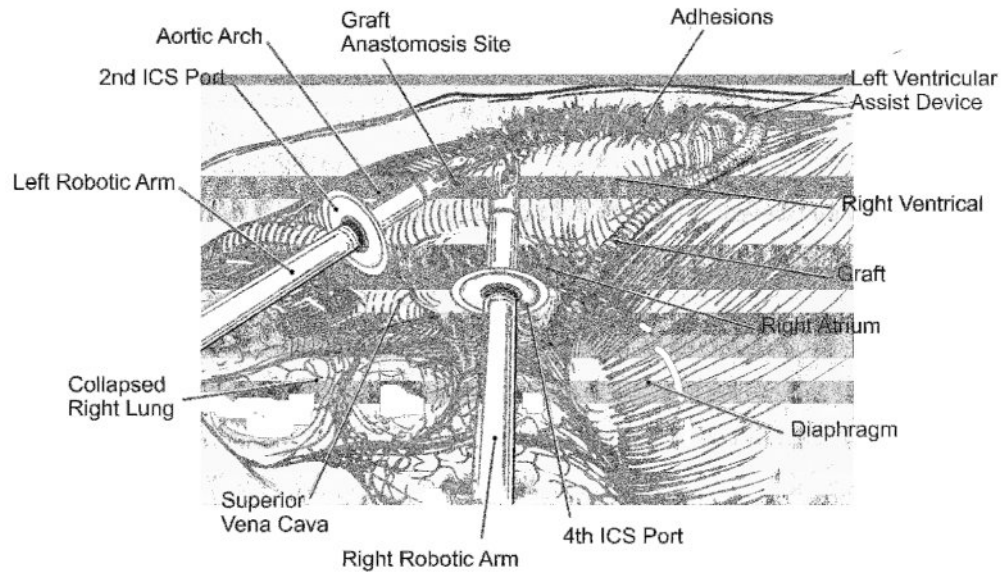
## References

1. Rose EA, Gelijns AC, Moskowitz AJ, Heitjan DF, Stevenson LW, Dembitsky W, et al. Randomized Evaluation of Mechanical Assistance for the Treatment of Congestive Heart Failure (REMATCH) Study Group. Long-term use of a left ventricular assist device for end-stage heart failure. *N Engl J Med.* 2001 Nov 15; 345(20):1435–43. [PubMed: 11794191]
2. George TJ, Beaty CA, Ewald GA, Russell SD, Shah AS, Conte JV, et al. Reoperative Sternotomy is Associated with Increased Mortality after Heart Transplantation. *Ann Thorac Surg.* 2012 Dec; 94(6):2025–32. [PubMed: 22959569]
3. Park CB, Suri RM, Burkhart HM, Greason KL, et al. Identifying Patients at Particular Risk of Injury During Repeat Sternotomy: Analysis of 2555 Cardiac Reoperations. *J Thorac Cardiovasc Surg.* 2010 Nov; 140(5):1028–35. [PubMed: 20951254]
4. Kamdar F, John R, Eckman P, Colvin-Adams M, Shumway SJ, Liao K. Postcardiac transplant survival in the current era in patients receiving continuous-flow left ventricular assist devices. *J Thorac Cardiovasc Surg.* 2013 Feb; 145(2):575–81. [PubMed: 23321132]
5. Cheung A, Lamarche Y, Kaan A, Munt B, Doyle A, et al. Off-Pump Implantation of the HeartWare HVAD Left Ventricular Assist Device Through Minimally Invasive Incisions. *Ann Thorac Surg.* 2011; 91:1294–1296. [PubMed: 21440172]
6. Haberl T, Riebandt J, Mahr S, Laufer G, Rajek A, Schima H, Zimpfer D. Viennese approach to minimize the invasiveness of ventricular assist device implantation. *Eur J Cardiothorac Surg.* Dec. 2013 :1–6.

7. Bartoli CR, Spence PA, Siess T, Raess DH, Koenig SC, Dowling RD. Nonphysiologic blood flow triggers endothelial and arterial remodeling in vivo: Implications for novel left ventricular assist devices with a peripheral anastomosis. *J Thorac Cardiovasc Surg.* 2013 Dec 8.



**Figure 1.**  
Sagittal view of the mediastinum from inside the right chest.



**Figure 2. Placement of robotic port sites and incisions with depiction of hVAD after implantation**